

<http://aif-doi.org/LJEEST/040211>

# Physiological and Histological Studies on Moringa Effects Against Liver Toxicity Induced by Hydroxychloroquine in Rats.

Barga Abou-khizam farag Abou-khizam.

## ARTICLE INFO

Vol.4 No. 2 Dec, 2022

Pages (81-90)

### Article history:

Revised form 09 October 2022

Accepted 12 November 2022

### Author affiliation

Environmental Sciences Department,  
Faculty of Sciences, University of  
Sebha, Libya.

faragabobake@yahoo.com

Tel: 0945731214

### Keywords:

*Moringa oleifera*, antioxidant,  
Hydroxychloroquine, rats.

## ABSTRACT

The goal of this study was to see how effective *Moringa oleifera* leaf powder was at protecting male rat's livers from hydroxychloroquine-induced liver damage. They were given dried Moringa leaf powder daily with meals orally for three weeks before being given different doses of hydroxychloroquine (1000, 500, and 250 mg / kg b.wt) daily for five days. In addition to the histology of the liver, the level of malondialdehyde (MDA), liver enzymes, and superoxide dismutase (SOD) enzyme activity were measured in the serum. The activity of liver enzymes and MDA increased when varied doses of hydroxychloroquine were given, but SOD activity decreased. Treatment with *Moringa oleifera* leaf powder lowers MDA levels and hepatic enzyme activity while increasing antioxidant enzyme activity. At the same time, the effects of hydroxychloroquine-induced tissue deterioration were improved when *Moringa oleifera* leaves were used. Finally, Moringa leaf powder increases antioxidant activity and reduces hydroxychloroquine-induced liver injury, suggesting that it could be used as a future liver injury prevention medication.

دراسات فسيولوجية و نسيجية على تأثيرات المورينجا ضد سمية الكبد التي يسببها

هيدروكسي كلوروكين في الفئران.

بارقة ابوخرام فرج أبوخرام

كان الهدف من هذه الدراسة هو معرفة مدى فعالية مسحوق أوراق المورينجا أوليفيرا في حماية كبد الفئران الذكور من تلف الكبد الناجم عن الهيدروكسي كلوروكين. تم إعطاؤهم مسحوق أوراق المورينجا المحفف يوميا مع وجبات الطعام عن طريق الفم لمدة ثلاثة أسابيع قبل إعطائهم جرعات مختلفة من هيدروكسي كلوروكين (1000 و 500 و 250 مجم / كجم من وزن الجسم) يوميا لمدة خمسة أيام. تم قياس مستوى نشاط إنزيم (MDA) malondialdehyde، وأنزيمات الكبد، ونشاط إنزيم (SOD) Superoxide في المصل. زاد نشاط إنزيمات الكبد و MDA عند إعطاء جرعات مختلفة من هيدروكسي كلوروكين، لكن نشاط SOD انخفض. يقلل العلاج بمسحوق أوراق المورينجا من مستويات MDA ونشاط إنزيم الكبد مع زيادة نشاط إنزيم مضادات الأكسدة، وفي الوقت نفسه، تم تحسين تأثيرات تدهور الأنسجة الناجم عن هيدروكسي كلوروكين عند استخدام أوراق المورينجا أوليفيرا. أخيراً، يزيد مسحوق أوراق المورينجا من نشاط مضادات الأكسدة ويقلل من إصابة الكبد التي يسببها هيدروكسي كلوروكين، مما يشير إلى أنه يمكن استخدامه كدواء للوقاية من إصابة الكبد في المستقبل. البلاستيك دقيق الحبيبات ومصادره وتركيزه بالترب الليبية لتلافي تفاعم هذه المشكلة في بلدنا مستقبلا.

**INTRODUCTION:**

The liver is a key player in the regulation of a number of physiological processes in our bodies. These include metabolic, secretory, and storage activities (Kumar *et al.*, 2011). It's also concerned about detoxing from a variety of medicines and xenobiotics. In this instance, the liver will be exposed to the toxicity of those sellers because the metabolic products of detoxification responses may be harmful to the liver when present in large quantities (Muriel, 2007). HCQ is a synthetic antimalarial medication that has long been the unbeatable first-line treatment for rheumatic diseases (Xin Qiao *et al.*, 2019). Hydroxychloroquine is widely utilised as an experimental liver toxicity model. Hepatocyte injury activates Kupffer cells, which secrete powerful mediators of the early inflammatory response, including reactive oxygen species (ROS), specifically superoxide anions, which are responsible for the formation of peroxynitrites and hydrogen peroxides (H<sub>2</sub>O<sub>2</sub>), resulting in oxidative pressure (Agarwal *et al.*, 2012). Antioxidants may desire to mitigate this oxidative injury caused by free radicals in two ways: by enhancing mobileular natural defences and/or by directly scavenging free radicals (Krinsky, 1992). Superoxide dismutase (SOD) is an antioxidant that can scavenge superoxide anions (Dunning *et al.*, 2013). The antioxidant response is important in protecting the liver from HCQ-induced damage. Recently, treatment with phytochemicals has emerged as a popular option for resolving hepato-toxications. The polyphenol extract of those phytochemicals has been discovered to reduce HCQ-induced liver damage via a free radical scavenging mechanism. Hassan *et al.* (2012). *Moringa oleifera* is a member of the Moringaceae family of plants. Its leaves are high in polyphenols, phenolic acids, vitamins, carotenoids, flavonoids, and alkaloids, among other macro- and micronutrients (Leone and colleagues, 2015). As a result, the *Moringa oleifera* plant is used to nourish both animals and humans as a top-notch nutritional supplement (Siddhuraju and Becker, 2003). It was long utilised as a traditional medical supply and was believed to treat a variety of ailments, earning it the moniker "wonder tree." Following that, the leaves were investigated for their anticancer, anti-inflammatory, hepato-protective, and antifungal properties (Monica *et al.*, 2010). Previous research, on the other hand, found that an ethanolic extract of *Moringa oleifera* leaves can effectively protect hepatic tissue from tissue damage induced by antitubercular drugs and acetaminophen (Fakurazi *et al.*, 2012). The goal of this study was to see if *Moringa oleifera* leaf powder might protect male rat's livers from hydroxychloroquine-induced liver damage.

**MATERIALS AND METHODS:**

Hydroxychloroquine sulphate (C<sub>18</sub>H<sub>26</sub>CLN<sub>3</sub>) used through this work obtained from EVA Group Limited, Egypt. Fresh *Moringa* Oliveira leaves were collected

during the month of January 2021 from a home garden, Libya and was identified and confirmed by Leaves were dried in shadow, crushed and kept in a clean tray until use. Experiments were carried on an adult male rats, purchased from Helwan Animal Station (Egypt), with body weight 180 g. Animals were housed 5 rats per cage at 24 ± 2 °C and subjected to 12 hours light /12 hours dark cycle. They were fed on a normal diet and allowed free access of water. Animals were maintained under these standard conditions for two weeks prior to the experiment for acclimatization.

Animals were randomly separated into 8 groups of 5 rats each at the end of the acclimation phase. Group I, served as the control group and were fed a normal diet, while Group II, were given *Moringa oleifera* Leaves powder mixed with meal, Group III, were given orally HCQ (1000 mg/kg b.wt) daily for 5 days, and Group IV, were given *Moringa oleifera* powder (2.7g/kg b.wt) daily for 5 days. After 3 weeks of mixing in the diet, HCQ (1000 mg/kg b.wt) was given orally for 5 days. For 5 days, Group V, were administered HCQ (500 mg/kg b.wt) orally, while Group VI, were given *Moringa oleifera* powder (2.7g/kg b.wt). After 3 weeks in the diet, Group VII, were given HCQ (250 mg / kg b.wt) orally for 5 days, Group VIII, were given HCQ (500 mg / kg b.wt) orally for 5 days, and Group VIII, were given *Moringa oleifera* powder (2.7g/kg b.wt) orally for 5 days. After 3 weeks of mixing in the diet, HCQ (250 mg/kg b.wt) was given orally for 5 days. Rats were fasted for 12 hours before being slaughtered under chloroform anaesthesia at the end of the experiment. Using sterile syringes, blood samples were taken directly from the heart. For biochemical testing, the blood was taken in clean, dry centrifuge tubes. Serum samples were collected by centrifugation at 4000 rpm for 15 minutes. Samples were maintained at -20 °C in clean Stoppard plastic vials until they were analysed. The liver was rapidly excised and rinsed in normal saline solution to eliminate any excess blood, and the liver lobe was preserved in 10% formalin for histological analysis.

Determination of liver function markers Alanine aminotransferase (ALT) activity and Aspartate aminotransferase (AST) activity using commercial diagnostic kits provided by Diamond Diagnostics, Cairo, Egypt, as well as the activity of Superoxide dismutase (SOD) enzyme and measurement malondialdehyde (MDA) in serum using Stocks and Donnandy (1971) technique using kits obtained from BIOMED Egypt. Liver tissues were collected from various groups and fixed in 10% neutral buffered formalin. Tissues were then dehydrated in ascending grades of ethyl alcohols, 70 percent, 90 percent, and 100 percent (to prevent shrinkage of tissues and remove water gradually from fixed tissues), cleared in xylol (to remove alcohol and allow the fixed tissues to be miscible with paraffin wax in the following step), and embedded in paraffin wax. The Cambridge Rocking Microtome was then used to cut serial transverse sections at a thickness of 5-6 microns and affix them to slides. Sections were stained

in Haematoxyline and Eosin (H&E) for the general histological study. dehydrated, cleared, and mounted with Canada balsam for permanent preparations (Saalu et al., 2008). Sections were examined under light microscopes and photographed.

The results were represented as mean standard deviation, and statistical analysis was carried out using ANOVA and a post hoc test (Duncan). It's a type of parametric statistical analysis that evaluates between- and within-group variance in order to determine differences between two or more groups. Statistical significance was defined as a P value of less than 0.05. SPSS version 20 was used to analyse the data.

## RESULTS AND DISCUSSION:

### i. Results

#### Liver function tests:

**Table (1):** Mean activity of alanine aminotransferase (ALT), and aspartate aminotransferase (AST) enzymes in sera of different experimental groups.

Groups Parameters	ALT (U/L) mean ± S.D	AST (U/L) mean ± S.D
Control	a 17.68± 53.20	a 59.75±190.60
Moringa	a 5.80 ±43.80	a 21.29±161.60
HCQ (1000mg/kg)	b44.61± 163.75	a 33.14±192.25
MO+HCQ (1000mg/kg)	a 17.27±57.40	a 48.71±219.00
HCQ (500mg/kg)	a 53.83±71.20	a 41.59±202.60
MO+ HCQ (500mg/kg)	a 28.34±75.00	b 50.08±239.75
HCQ (250mg/kg)	a 16.29±77.25	c 34.73±271.25
MO+HCQ (250mg/kg)	a 46.45±94.00	b 83.11±258.40
P-value(P)	0.000***	0.04*
Decision	Ex-Sig***= (P<0.001)	Sig*= (P<0.05)

Data are expressed as mean ± S.D. (N=5 in each group). (\*) significant,  $p \leq 0.05$  and (\*\*\*) Extremely significant,  $p \leq 0.001$  versus those of the control group. a, b, c means having different superscript letters in the same column differ significantly ( $P < 0.05$ ), HCQ= hydroxychloroquine, MO = Moringa.

#### Antioxidant Enzymes (Stress Marker)

##### Superoxide dismutase (SOD):

Table 2 showed that, there is a significant difference between different doses of HCQ group compared with groups treated by *Moringa oleifera*. Where

##### Lipid Peroxidation Product (Oxidative Stress Marker) Malondialdehyde (MDA):

And Table 2 also showed that, there is a significant difference between different doses of HCQ compared with control group. Where recorded very significant increase in with different doses of

Table (2): The mean activity of superoxide dismutase (SOD) enzymes and malondialdehyde (MDA) level, in sera of rats of different experimental groups.

Activity of serum alanine aminotransferase (ALT) and serum aspartate aminotransferase (AST):

The activity of the ALT enzyme in the blood serum of the experimental groups was not significantly different from the control group. In contrast, the hydroxychloroquine group (1000mg/kg) had an exceptionally significant rise ( $P < 0.001$ ) in ALT activity in serum when compared to the control group and the other groups ( $P < 0.05$ ), as shown in Table 1 rats given HCQ with *Moringa oleifera*, on the other hand, exhibited significant improvements in all of these liver function tests when compared to rats given HCQ alone. Table 1 further revealed that there was no significant difference in the activity of AST in Moringa groups' blood serum compared to the control group. In contrast, after administration of various dosages of hydroxychloroquine, significant increases in AST activity in serum were seen as compared to the control group.

recorded significant increase in the groups treated by *Moringa oleifera* and that gave different doses of hydroxychloroquine compared to the different doses of hydroxychloroquine groups at P value  $< 0.001$ .

hydroxychloroquine groups compared to the groups treated by *Moringa oleifera* at P value  $< 0.01$ .

Groups	SOD (U/mL) mean $\pm$ S.D	MDA (nM/ml) mean $\pm$ S.D
Control	b 46.48 $\pm$ 203.58	a 3.22 $\pm$ 16.86
Moringa	a 36.68 $\pm$ 139.06	a 5.08 $\pm$ 16.86
HCQ (1000mg/kg)	c 28.44 $\pm$ 214.60	a 5.14 $\pm$ 25.42
MO+HCQ (1000mg/kg)	a 30.19 $\pm$ 137.24	b 13.01 $\pm$ 27.24
HCQ (500mg/kg)	a 53.38 $\pm$ 183.52	b 6.89 $\pm$ 27.70
MO+ HCQ (500mg/kg)	a 24.56 $\pm$ 130.52	b 4.77 $\pm$ 29.05
HCQ (250mg/kg)	a 39.31 $\pm$ 125.62	b 5.12 $\pm$ 28.36
MO+HCQ (250mg/kg)	a 37.04 $\pm$ 104.16	c 8.99 $\pm$ 36.36
P-value(P)	0.001***	0.003**
Decision	Ex-Sig***= (P<0.001)	Very-Sig**= (P<0.01)

Data are expressed as mean  $\pm$  S.D. (N=5 in each group) .(\*\*) Very significant,  $p \leq 0.01$  and (\*\*\*) Extremely significant,  $p \leq 0.001$  versus those of the control group. a, b, c means having different superscript letters in the same column differ significantly ( $P < 0.05$ ), HCQ= hydroxychloroquine, MO = Moringa.

#### Histopathological analysis:

##### 1-Histopathological of liver in control group:

Sections of normal rat's liver confirmed the ordinary shape of the liver tissue. The essential structural element of the liver is hepatocyte. These hepatocytes are disposed in plates which are interconnected in one of these was to show in the light microscope sections, structural units, the liver lobules. The liver lobule is shaped of a polygonal mass of tissue with centrally located central vein and some portal spaces at the periphery of the lobule, every containing a veinule (a department of the portal vein); an arteriole (a department of the hepatic artery); and ductile (a part of a bile duct system) Figure 1 (A&B).

##### 2- Histopathology of the liver in rats that were given Moringa for 3 weeks:

When sections of the liver from non-injected and Moringa-treated rats were stained with hematoxylin and eosin, they revealed normal hepatocytes and a thin layer of periportal fibrous connective tissue, with no indication of pathological damage (H&E). Figure 2 (C&D).

##### 3- Histopathological of liver in the rats gave HCQ dose 1000 mg/kg:

When stained with hematoxylin and eosin, the hepatic section revealed some dilated blood sinusoids in Hydroxychloroquine-induced periportal hepatic vacuolation with dark pyknotic nuclei and bile duct proliferation in rats (H&E). Figure 3 (E&F).

##### 4- Histopathological of liver in the rats gave HCQ dose 1000 mg/kg and treated with Moringa prophylactically for 3 weeks:

Sections of the liver in the rats that gave Hydroxychloroquine and treated with Moringa showed still a small number of decomposing erythrocytes and

infiltration within some of the sinuses as well as central venous congestion and showed a marked improvement in the structure of the liver tissue as can be seen by the decreased post-translational hypertrophy of the epithelium lining the bile duct And normal periportal hepatocytes in the liver both were stained with hematoxylin and eosin stain (H&E). Figure 4, (G&H).

##### 5- Histopathological of liver in the rats gave HCQ dose 500 mg/kg:

Histopathological exam of liver sections of Hydroxychloroquine that gave rats confirmed in liver, showed sinusoidal dilatation in addition to congested dilated vital vein periportal hepatic vacuolation with darkish pyknotic nuclei and bile duct proliferation while stained via way of means of hematoxylin and eosin stain (H&E). Figure 5, (I&J).

##### 6- Histopathological of liver in the rats gave HCQ dose 500 mg/kg and treated with Moringa for 3 weeks:

Sections of the liver in the rats that gave Hydroxychloroquine and dealt with Moringa showed marked development in liver tissues shape as may be located through reduced the diploma of mailed hyperplasia of the liner epithelium of the bile duct and regular periportal hepatic cells in liver and they had been stained through hematoxylin and eosin stain (H&E). 6th Figure, (K&L).

##### 7- Histopathological of liver in the rats gave HCQ dose 250 mg/kg:

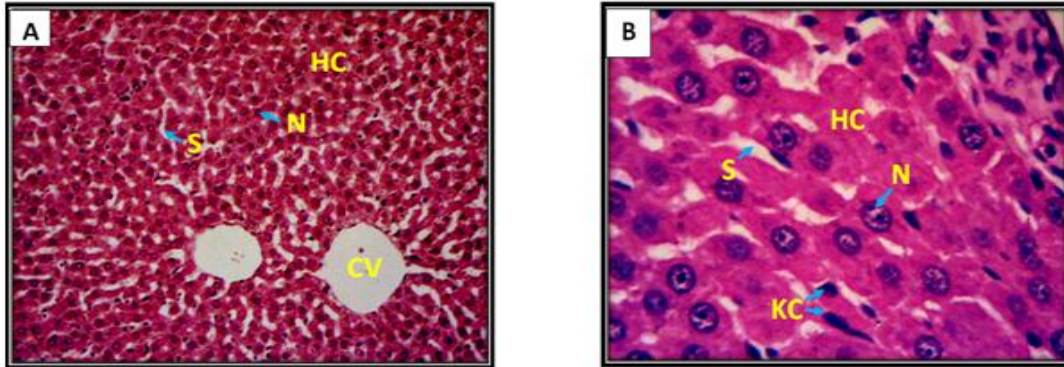
Histopathological examination of liver sections of Hydroxychloroquine that gave rats showed in liver, periportal hepatic vacuolation with dark pyknotic nuclei

and bile duct proliferation when stained by hematoxylin and eosin stain (H&E). 7th Figure, (M&N).

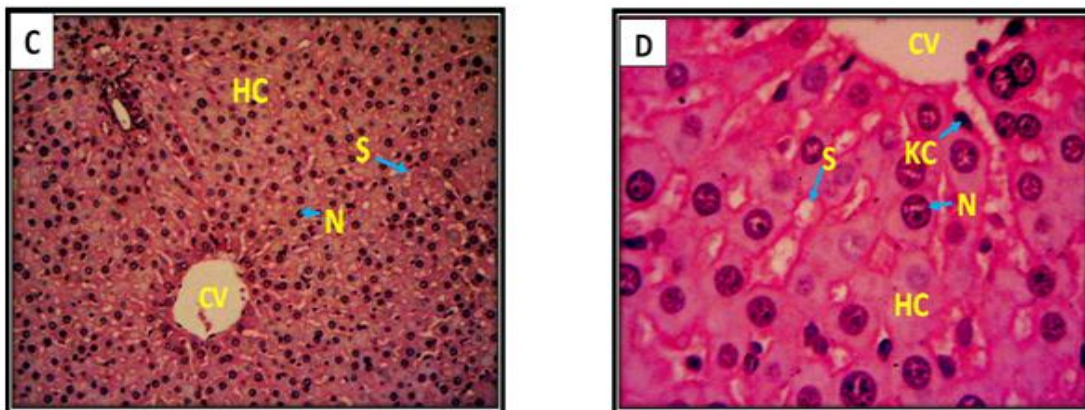
**8- Histopathological of liver in the rats gave HCQ doses 250 mg/kg and treated with Moringa for 3 weeks:**

Showed normal hepatocytes and thin layer of

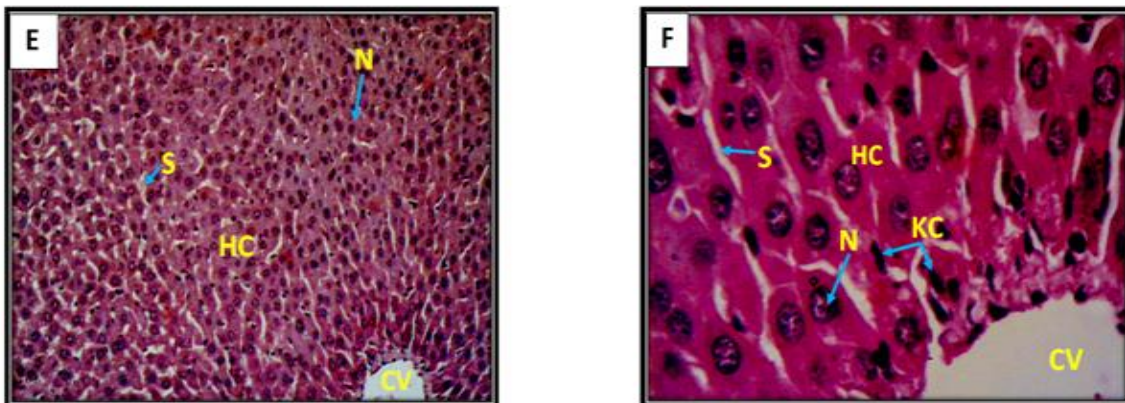
periportal fibrous connective tissue, with no evidence of pathological damage, when they were stained by hematoxylin and eosin. (H&E). 8th Figure, (O&P).



**Fig. 1.** Photomicrograph of rat Liver tissue. Control group I (A&B). Showing the hepatocytes (HC), central vein (CV), nucleus (N), and sinusoid (S). (H&E, A; 100X). Kupffer's cells (KC). (H&E, B; 400X).

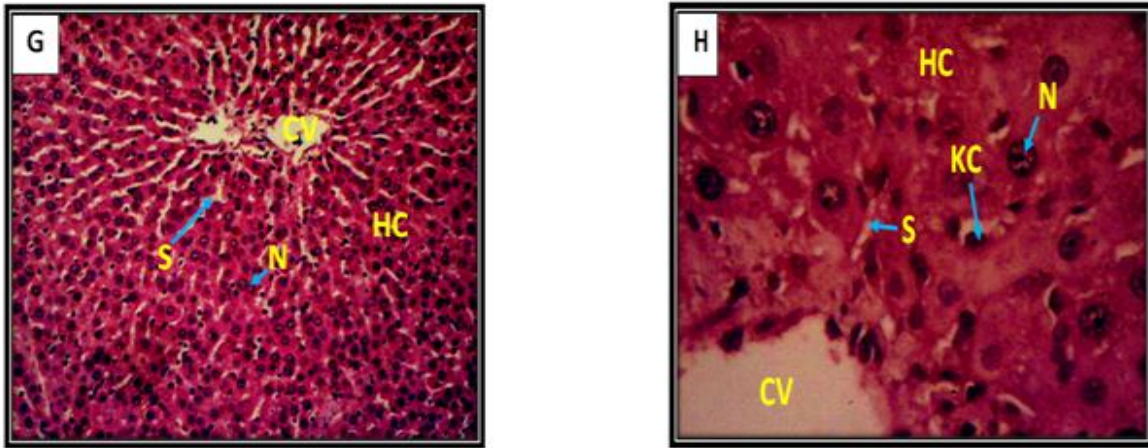


**Fig. 2.** Photomicrograph of rat Liver tissue. Group II (Control Moringa) (C&D). Showing the hepatocytes (HC), central vein (CV), nucleus (N), and sinusoid (S). (H&E, C; 100X). Kupffer's cells (KC). (H&E, D; 400X).

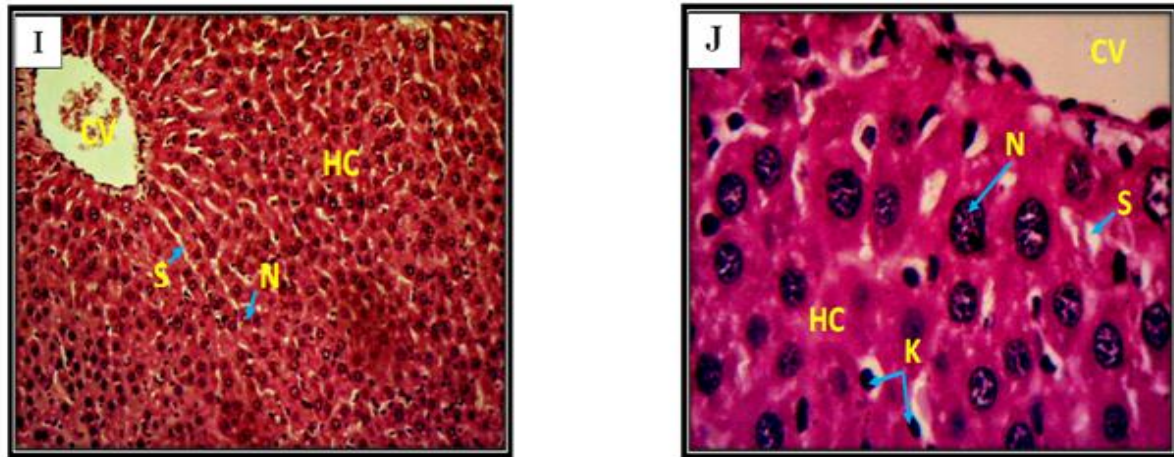


**Fig.3.** Photomicrograph of rat Liver tissue. group III (E&F) rats injected with dose of hydroxychloroquine (1000 mg / kg ) Showing the hepatocytes (HC), central vein (CV), nucleus(N), sinusoid (S). (H&E, E; 100X). Kupffer's cells (KC). (H&E, F; 400X).

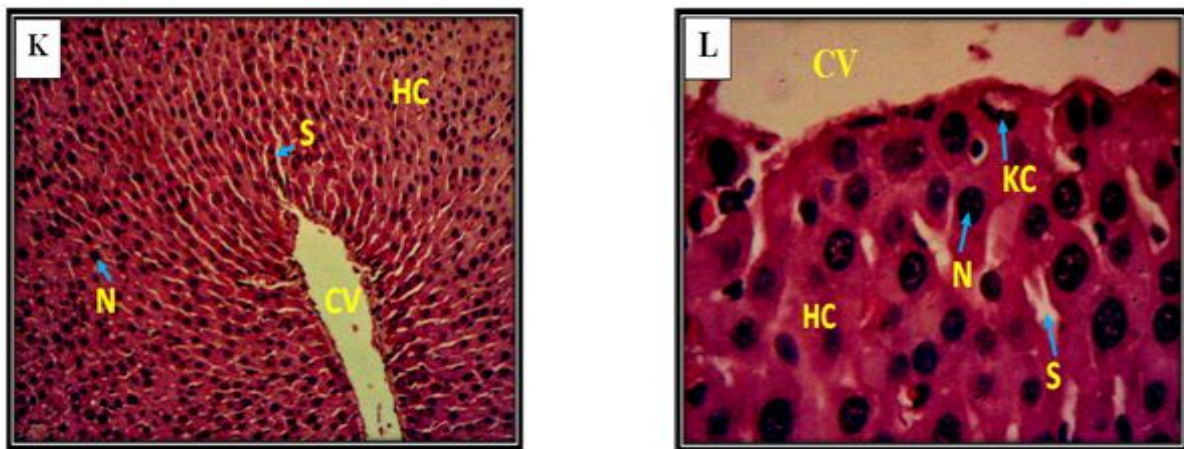




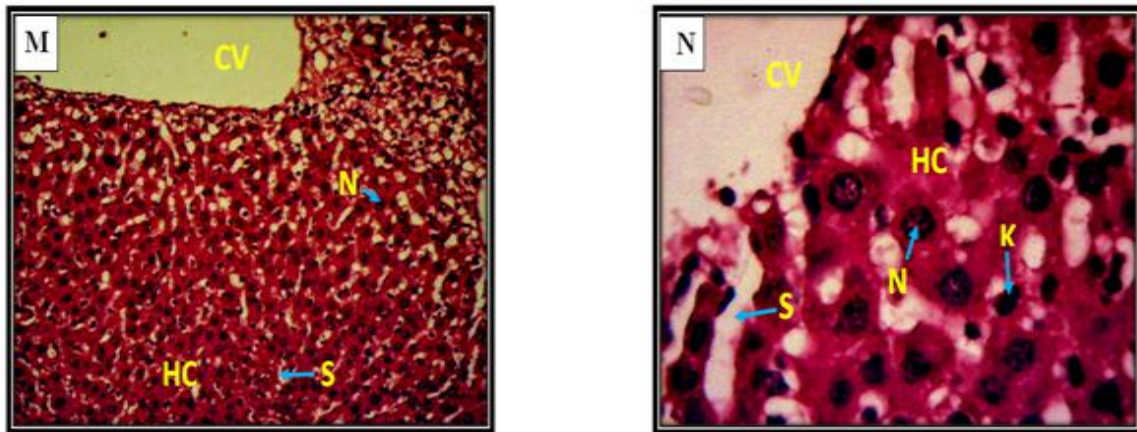
**Fig. 4.** Photomicrograph of rat Liver tissue. Group IV (G&H) rats injected with dose of hydroxychloroquine 1000 mg / kg & treatment with *Moringa*. Showing the hepatocytes (HC), central vein (CV), nucleus (N), and sinusoid (S). (H&E, G; 100X). Kupffer's cells (KC). (H&E, H; 400X).



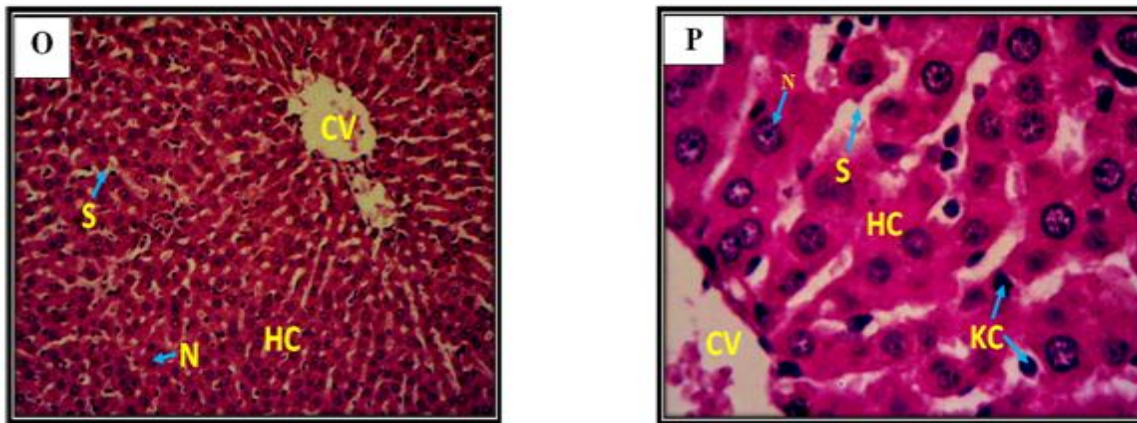
**Fig. 5.** Photomicrograph of rat Liver tissue. Group V (I & J) rats injected with dose of hydroxychloroquine 500 mg / kg) Showing the hepatocytes (HC), central vein (CV), nucleus (N), sinusoid (S). (H&E, I; 100X). Kupffer's cells (KC). (H & E, J; 400X).



**Fig. 6.** Photomicrograph of rat Liver tissue. Group VI (K&L) rats injected with dose of hydroxychloroquine 500 mg / kg & treatment with *Moringa*. Showing the hepatocytes (HC), central vein (CV), nucleus (N), and sinusoid (S). (H&E, K; 100X). Kupffer's cells (KC). (H & E, L; 400X).



**Fig. 7.** Photomicrograph of rat Liver tissue. Group VII (M& N) rats injected with dose of hydroxychloroquine 250 mg / kg) Showing the hepatocytes (HC), central vein (CV), nucleus (N), sinusoid (S). (H&E, M; 100X). Kupffer's cells (KC). (H & E, N; 400X).



**Fig. 8.** Photomicrograph of rat Liver tissue. Group VIII (O&P) rats injected with dose of hydroxy chloroquine 250 mg / kg & treatment with Moringa. Showing the hepatocytes (HC), central vein (CV), nucleus (N), and sinusoid (S). (H&E, O; 100X). Kupffer's cells (KC). (H & E, P; 400X).

## ii. Discussion:

Borba *et al.* (2004) employed hydroxychloroquine (HCQ) in the treatment of malaria and inflammatory disorders such rheumatoid arthritis and systemic lupus erythematosus, as well as the management of a number of viral diseases like influenza, SARS-CoV, and HIV (Takano *et al.*, 2013). Recently, national and international medical bodies around the world approved the use of chloroquine and HCQ to treat Corona virus (COVID-19) in some hospitalised patients (Bensalah *et al.*, 2020).

When used long-term, it becomes toxic, causing negative effects on tissue such as liver tissue damage, kidney damage, and other members (El Shishtawy *et al.* 2013). Increased serum aminotransferase activity, particularly ALT, is a

common indicator of hepatocellular membrane injury (Jaeschke *et al.*, 2013).

In this investigation, different dosages of HCQ were given to rats, and the serum activity of ALT and AST were increased. As a result, giving HCQ to rats caused oxidative stress, which led to hepatic cell damage and dysfunction. Of previous studies, Fernandez, (2017). Observed damage in the DNA in rat liver slices exposed to HCQ and suggested that HCQ could induce genotoxicity and subsequently affects the synthetic functions of liver.

Following exposure to various doses of HCQ (1000, 500, and 250 mg/kg), enhanced hepatic tissue transaminase activity (ALT and AST) was also seen. This revealed that HCQ had a negative impact on liver function in the treated animals. The current investigation discovered that after *M.oleifera* treatment, HCQ administration caused significant reductions in serum levels of ALT and AST. The reduction in ALT and AST activities as a result of



*M.oleifera* leaves points to an early improvement in the cellular membrane integrity of the hepatic cell, which is a clear demonstration of their anti-hepatotoxic activity. When rheumatoid arthritis is treated, the activities of ALT and AST are reduced. When treatment of rats injected with different dose HCQ with *M. oleifera* leaves.

in the present study was consistence with Karthivashan *et al.*, (2015). Who found that *M.oleifera* leaves effectively decreases the severity of the acetaminophen-induced liver damage, which was evidenced by low levels of ALT and AST in the serum of *M.oleifera* treated rates, thus indicating reduced hepatic damage. Also, these results are parallel with Toppo *et al.*, (2015) who demonstrated that treatment of rats with *M.oleifera* leaves has shown protection against cadmium-induced hepatotoxicity represented by significantly decreased the elevated ALT,AST, levels as compared to cadmium chloride treated group. Similar study was reported by Taha *et al.* (2015) who showed that co-administration of *M.oleifera* leaves with Diclofenacefficiently reduced the DIC induced elevation of serum AST, ALT, indicating a promising hepatoprotective activity of *M.oleifera*.

The focus of the Present study was to assess the efficacy and effects of *M. oleifera* leaves on rats treated with hydroxychloroquine in rat model. And the results of the study showed that, the antioxidant protection mechanisms consist of enzymatic and non-enzymatic antioxidants gambling a large position withinside the maintaining position withinside the maintaining of physiological ranges of O<sub>2</sub> and H<sub>2</sub>O<sub>2</sub> and removing the peroxides generated from inadvertent publicity to poisonous drugs. Among the antioxidant enzymes, SOD is the primary line of protection towards HCQ prompted hepatic oxidative harm. SOD is the number one step of the protection mechanism withinside the antioxidant gadget towards oxidative strain with the aid of using catalyzing the dismutation of superoxide radicals (O<sub>2</sub>) into molecular oxygen (O<sub>2</sub>) and hydrogen peroxide (H<sub>2</sub>O<sub>2</sub>). (Kirkman *et al.*, 1987). The effects of the existing examine discovered that, HCQ management prompted oxidative strain which changed into manifested with the aid of using the large increase (p<0.001) in MDA ranges in blood that is a prime aldehyde attributable to the peroxidation of organic tissue and it's far an indicator of tissue harm because of the large reduction (p<0.05) in SOD activities. (Glasauer and Chandel, 2014).The mechanism may also contain the participation ofthe latter's withinside the

scavenging cappotential of the cells and, thus, the discounts of their suggest values mediated the overproduction of MDA. Our consequences have been coincided with (Koracevic *et al.*, 2001), in that HCQ management led to a large elevation in MDA and hobby of antioxidant enzymes, SOD in hepatic tissue.

The liver tissue of Hydroxychloroquine-injected rats displayed per portal hepatic vacuolation with dark pyknotic nuclei, bile duct proliferation, and enhanced per portal fibrous connective tissue, according to histopathological findings. In another study, the histopathological evaluation of the liver indicated dilation of the central vein, vacuolization, degeneration of hepatocytes and pyknotic nuclei. Pari and Amali (2005). Rats treated with *M.oleifera* for (3 weeks), liver tissues showed significant improvement which could be seen with reduced degree of hepatomegaly and thinner fibrous layer.

The histopathological results of this study showed that rats gave HCQ in different doses, developed severe liver injury and fibrosis, as evidence of the marked inflammatory changes, and deformation in the structure of the liver. However, preemptively treating rats with *M.oleifera* for (3 weeks), showed moderate improvement in inflammatory changes and fibrosis. These results indicated that treatment with *M.oleifera* attenuated the inflammation caused by treatment with HCQ, which may be due to its antioxidant effects. Un gave rats reated with *M.oleifera* for (3 weeks), showed normal histological changes, similar to those of normal rats.

#### CONCLUSION:

- 
- HCQ administration with different dose cases disorders of kidney function and tissue of rats
2. HCQ at a dose (1000 mg / kg b.wt) is the more dangers dose.2.
  3. From the results of present study, one can conclude that *Moringa* can contribute to protecting kidney cells in rats from damages caused by to hydroxychloroquine by reducing kidney inflammation and relieving oxidative stress.
  4. The maximum protective Effects of *Moringa oleifera* was against HCQ (250 mg / kg b.wt).  
synthase knockout mice. *J Pharmacol Exp Ther*, 340(1): 134–142.

#### REFERENCES :

-----

Agarwal, R., Hennings, L., Rafferty, T.M., Letzig, L.G., McCullough, S. and James, L.P., 2012. Acetaminophen-induced hepatotoxicity and protein nitration in neuronal nitric-oxide

Bensalah, N., Midassi, S., Ahmad, M.I. and Bedoui, A., 2020. Degradation of hydroxychloroquine by electrochemical advanced oxidation processes. *Chem. Eng. J.* 402:126-279.



- Borba, E.F., Turrini-Filho, J.R., Kuruma, K.A., Bertola, C., Pedalini, M.E., Lorenzi, M.C. and Bonfá, E., 2004. Chloroquine gestational use in systemic lupus erythematosus: assessing the risk of child ototoxicity by pure tone audiometry. *Lupus PubMed* 13: 223–227.
- Dunning, S., Ur Rehman, A., Tiebosch, M.H., Hannivoort, R.A., Haijer, F.W. and Woudenberg, J. 2013. Glutathione and antioxidant enzymes serve complementary roles in protecting activated hepatic stellate cells against hydrogen peroxide-induced cell death. *J Biochim Biophys Acta*, 1832(12): 2027–2034.
- El Shishtawy, M., Elgendy, F. S. and Ramzy, R., 2013. Comparative toxicity study of chloroquine and hydroxychloroquine on adult albino rats. *Mansoura J. Forensic Med. Clin. Toxicol.* 21: 15–28.
- Fakurazi, S., Sharifudin, S.A. and Arulsevan, P., 2012. *Moringa oleifera* hydroethanolic extracts effectively acetaminophen-induced hepatotoxicity in experimental rats through their antioxidant nature. *Molecules, J BiSE* 17:8334-8350.
- Fernandez, A.P., 2017. Updated recommendations on the use of hydroxychloroquine in dermatologic practice. *J. Am. Acad. Dermatol.* 76 (6), 1176–1182.
- Glasauer, A. and Chandel, N.S., 2014. Targeting antioxidants for cancer therapy. *Biochemical Pharmacology* 92:90-101.
- Hassan, M.H., Edfawy, M., Mansour, A. and Hamed, A.A. 2012. Antioxidant and antiapoptotic effects of capsaicin against carbon tetrachloride-induced hepatotoxicity in rats. *J Toxicol Ind Health*, 28(5): 428–438.
- Jaeschke, H., Williams, C.D., McGill, M.R., Xie, Y. and Ramachandran, A., 2013. Models of drug-induced liver injury for evaluation of phytotherapeutics and other natural products. *J Food Chem. Toxicol.*, 55: 279-289.
- Karthivashan, G., Arulsevan, P., Tan, S. and Fakurazi, S., 2015. The molecular mechanism underlying the hepatoprotective potential of *Moringa oleifera* leaves extract against acetaminophen induced hepatotoxicity in mice. *J. Func. Foods*, 17: 115-126.
- Kirkman, H.N., Galiano, S. and Gaetani, G.F., 1987. The function of catalase bound NAD PH. *J. Biol. Chem.*, 262: 660-665.
- Koracevic, D., Koracevic, G., Djordjevic, V., Andrejevic, S. and Cosic, V. 2001. Method for the measurement of antioxidant activity in human fluids. *J. Clin. Pathol.* 54: 356–361.
- Krinsky, N.I. 1992. Mechanism of action of biological antioxidants. *J Proc Soc Exp Biol Med*, 200: 248–254
- Kumar, C.H., Ramesh, A., Suresh Kumar, J.N. and Mohammed I.B., 2011. A review on hepatoprotective activity of medicinal plants. *Int J Pharmaceut Sci Res*, 23: 501– 515.
- Leone, A., Spada, A., Battezzati, A., Schiraldi, A., Aristil, J. and Bertoli, S., 2015. Cultivation, genetic, ethnopharmacology, phytochemistry and pharmacology of *moringa oleifera* leaves: an overview. *Int J Mol Sci*, 16: 12791–12835.
- Monica, P.H.K., Sharma, B., Sarkar, C. and Singh, C., 2010. Kinetics of drumstick leaves (*Moringa oleifera*) during convective drying. *African J Plant Science*, 4 (10): 391– 400.
- Muriel, P. and Sahu, S.C., 2007. Some experimental models of liver damage. In *Hepatotoxicity From genomics to in vitro and in vivo models, J West Sussex, England; Wiley*: 119–137.
- Pari, L. and Amali, D.R., 2005. Protective role of tetrahydrocurcumin (THC) an active principle of turmeric on chloroquine induced hepatotoxicity in rats. *J. Pharm. Pharm. Sci.* 8: 115–123.
- Reitman, S. and Frankel, S., 1957. A colorimetric method for the determination of serum glutamic oxalacetic and glutamic pyruvic transaminases. *American J Clinical Pathology* 28:56-63.
- Saalu, L.C., Jewo, P.I., Fadeyebi, I.O. and Ikueerowo, S.O., 2008. The effect of unilateral varicocele on contralateral testicular Histo – morphology in Ratus Norvegicus. *J. Med. Sci.*, 8(7): 654-655.
- Siddhuraju, P. and Becker, K., 2003. Antioxidant properties of various solvent extracts of total phenolic constituents from three different agroclimatic origins of drumstick tree (*Moringa oleifera* Lam.) leaves. *J Agricultural and Food Chemistry*, 51(8): 2144– 2155.
- Stocks, J. and Donnandy, T., 1971. The autooxidation of human red cell lipids induced by hydrogen peroxide. *Br. J. Haematol.*, 20: 95-111.
- Taha, N.R., Rabah, S.O., Shaker, S.A. and Mograby, M.M., 2015. Effect of *Moringa oleifera* leaves on diclofenac sodium induced hepatic injury in albino rats: ultrastructural and immunohistochemical studies. *J. Cytol. Histol.* 6(2): 315.
- Takano, T., Katoh, Y., Doki, T. and Hohdatsu, T., 2013. Effect of chloroquine on feline infectious peritonitis virus infection in vitro and in vivo. *J Antiviral Res.* 99: 100–107.

Toppo, R., Roy, B.K., Gora, R.H., Baxla, S.L. and Kumar, P., 2015. Hepatoprotective activity of *Moringa oleifera* against cadmium toxicity in rats. *J Veterinary World*, 8(4): 537-540.

Xin Qiao, X., Zhuo-Chao, O., Zhou, I. and Rui Niu, Q., 2019. Hydroxychloroquine Improves

Obesity-Associated Insulin Resistance and Hepatic Steatosis by Regulating Lipid Metabolism Department of Rheumatology and Immunology. *frontiersin J pharmacology* 12:120-126.